Dario Leosco
Dipartimento di Scienze Mediche Traslazionali
Università degli Studi di Napoli Federico II

Valvulopatia e Cardiomiopatia Amiloidotica

Aortic Stenosis and ATTR

75 y/o male presented to the emergency department with acute dyspnea

- no history of previous cardiac or pulmonary disease
- moderate periperal edema
- risk factor: ex-smoker
- Laboratory:
  - NT pro-BNP: 1820 ng/L
  - Creatinine: 1.5 mg/dl
  - **Troponin T: 90 pg/ml**

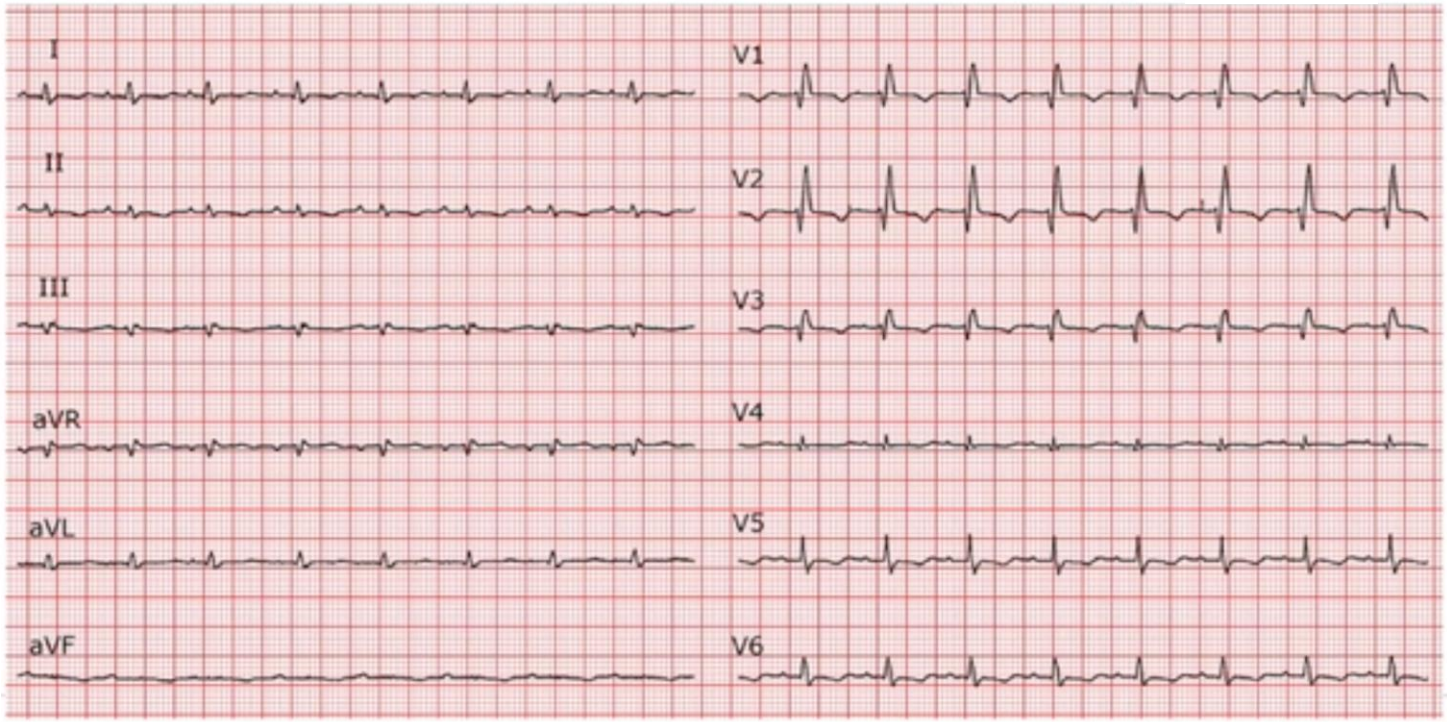

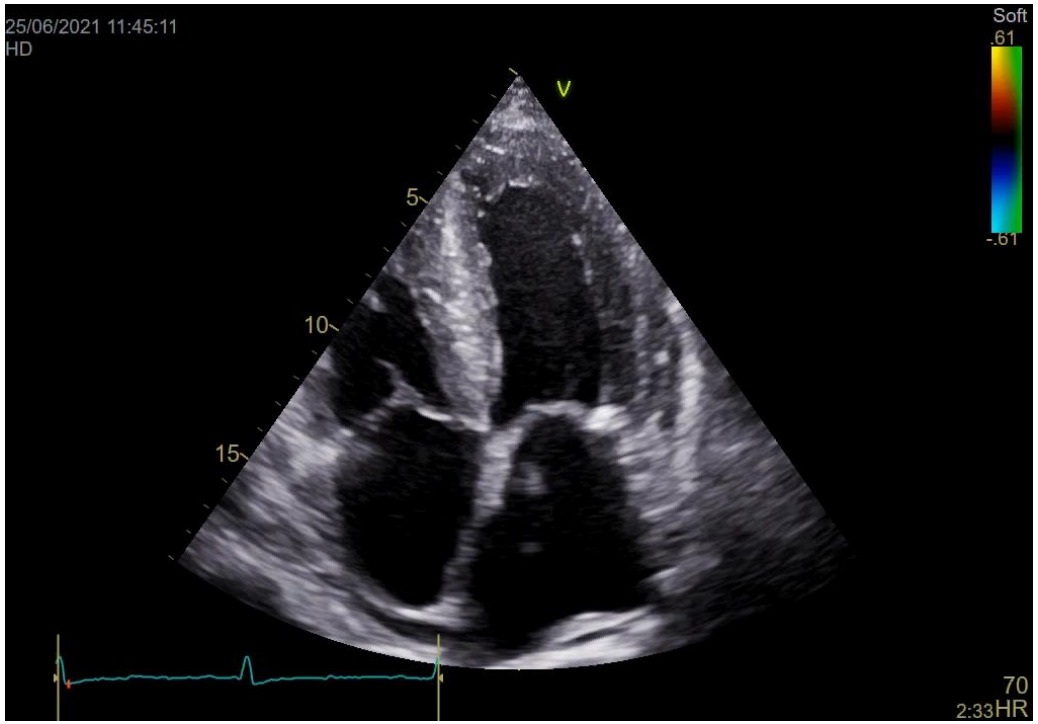

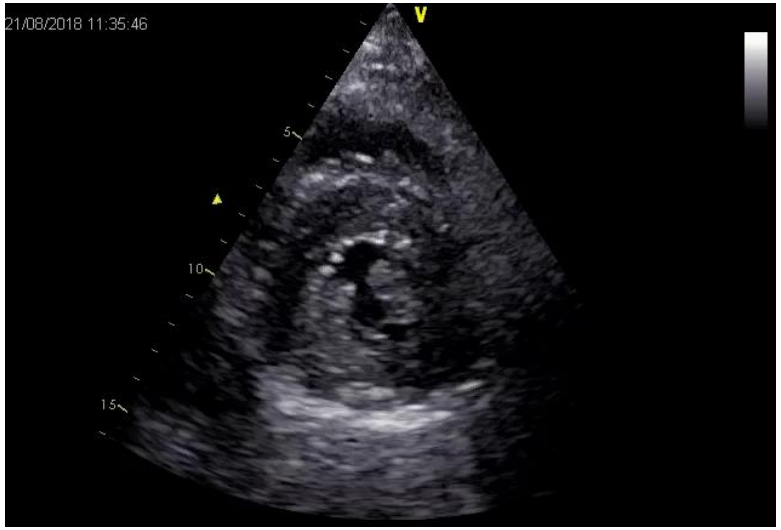

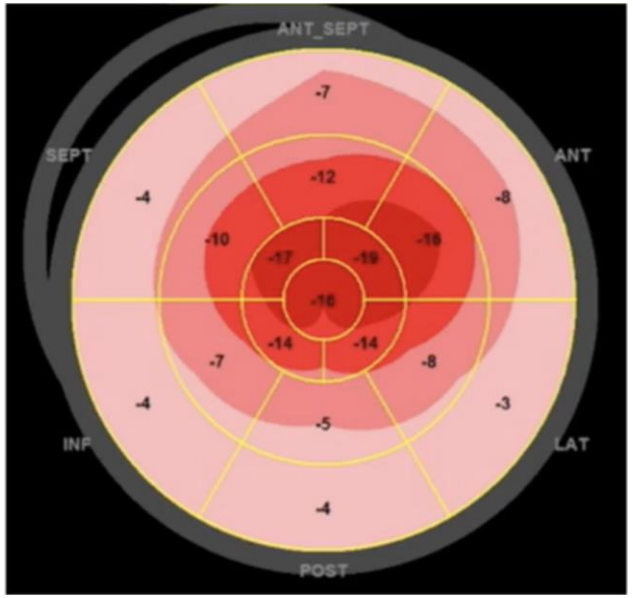

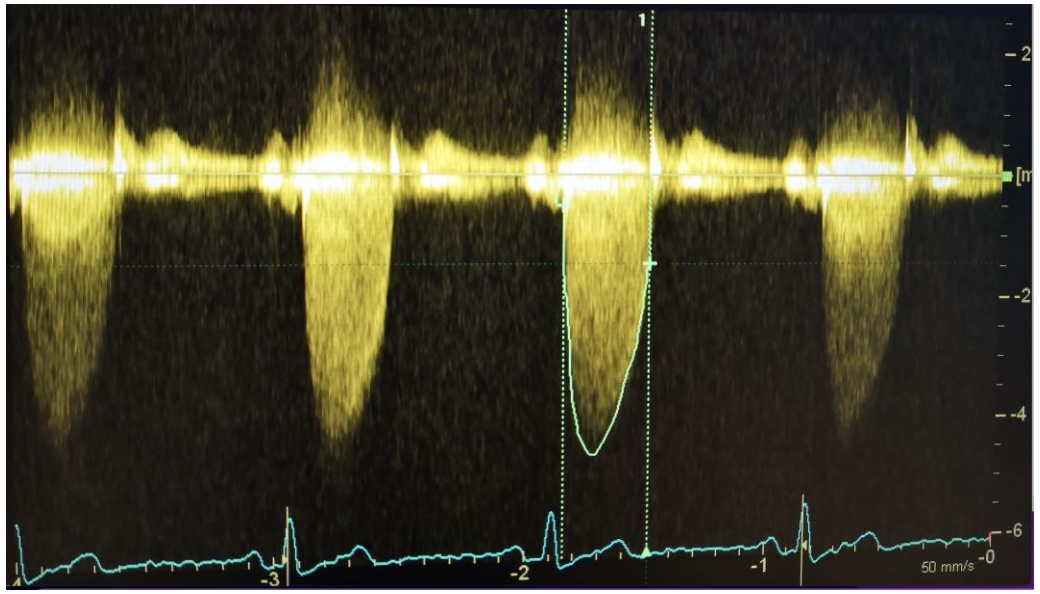

Mean delta P: 45 mmHg

AVA: 0.7

Biventricular hypertrophy

Biventricular impairment

Bi-atrial dilatation

High myocardial T1 (1116ms by ShMOLLI)

Abnormal nulling on TI scout

Global late gadolinium enhancement which is transmural basally and endocardial towards the apex.

High ECV at 52% (only seen in amyloidosis - previous highest in aortic stenosis 0.41).

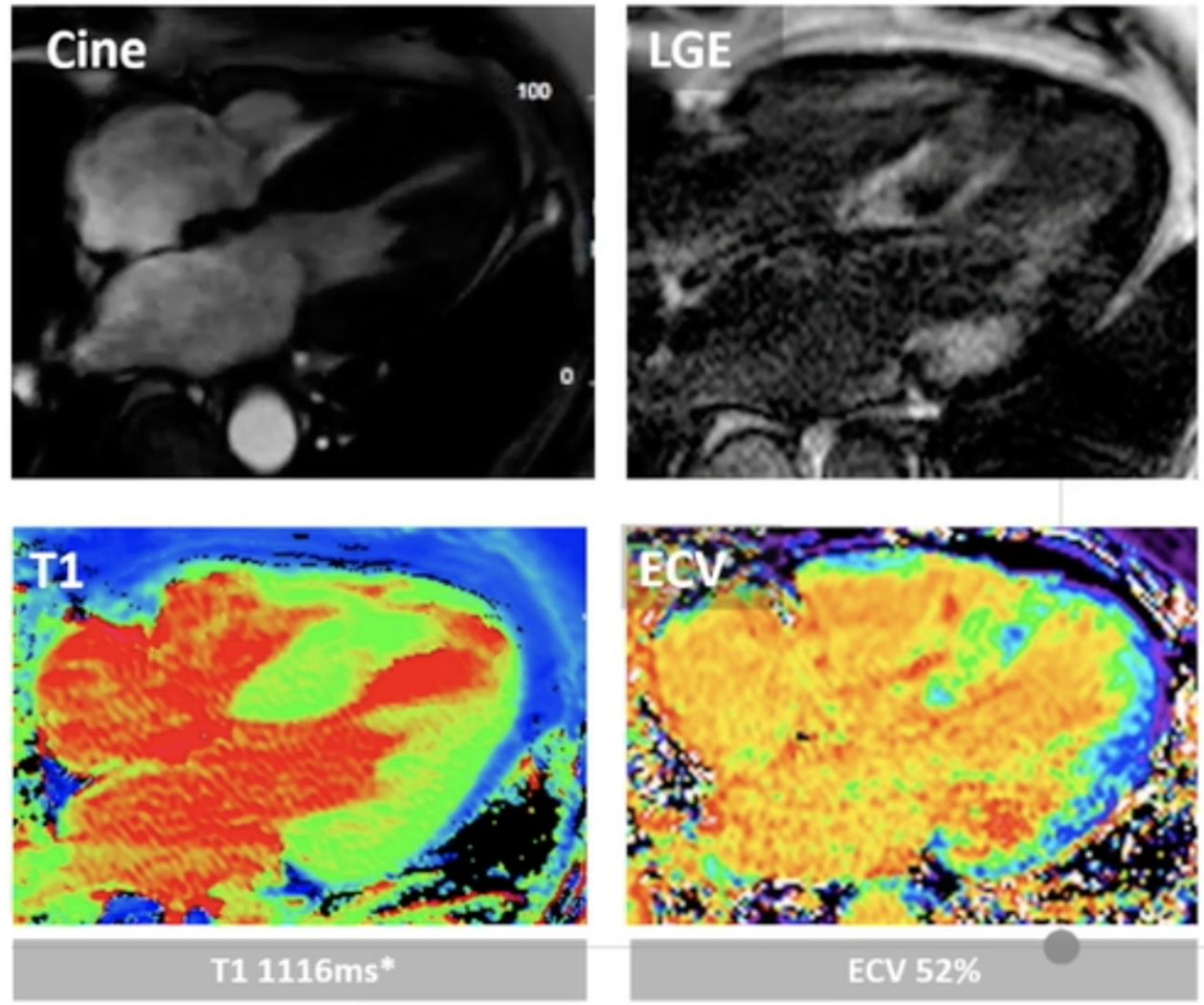

*normal range T1 960+/-60ms

*normal range ECV 26+/-2%

80 y/o male

- Laboratory analysis:
  No light-chains in blood / urine

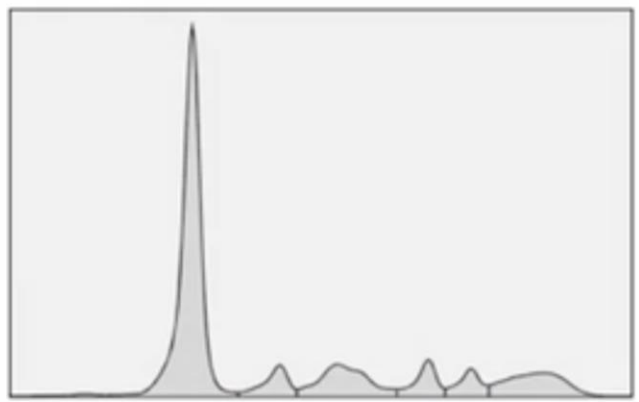

- Bone-Scintigraphy:
  Cardiac enhancement
  Perugini Grade III

What would you do next?

1. Conservative treatment, this is a lost case
2. Surgical AVR
3. TAVR
4. Pharmacotherapy with Tafamidis

Cardiac amyloidosis in severe aortic stenosis undergoing TAVR

ESC Council Valvular Heart Disease

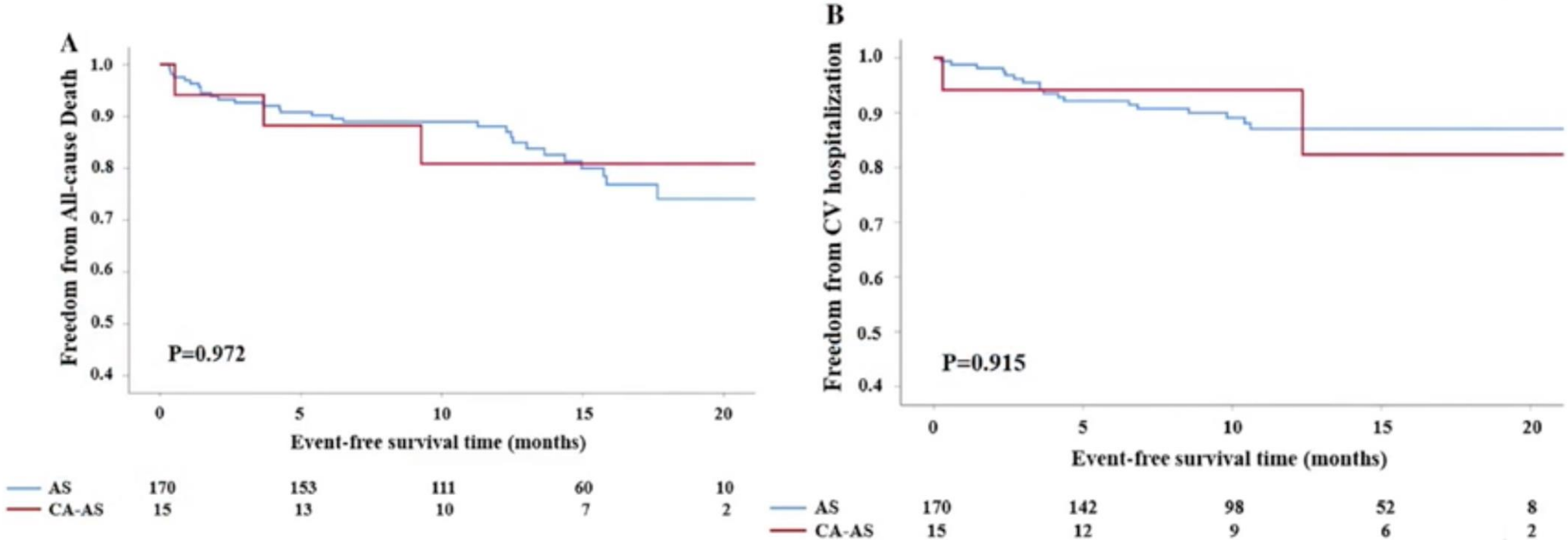

Nitsche, Mascherbauer. European Journal of Heart Failure 2020

Aortic valve intervention in AS-ATTR

ESC Council Valvular Heart Disease

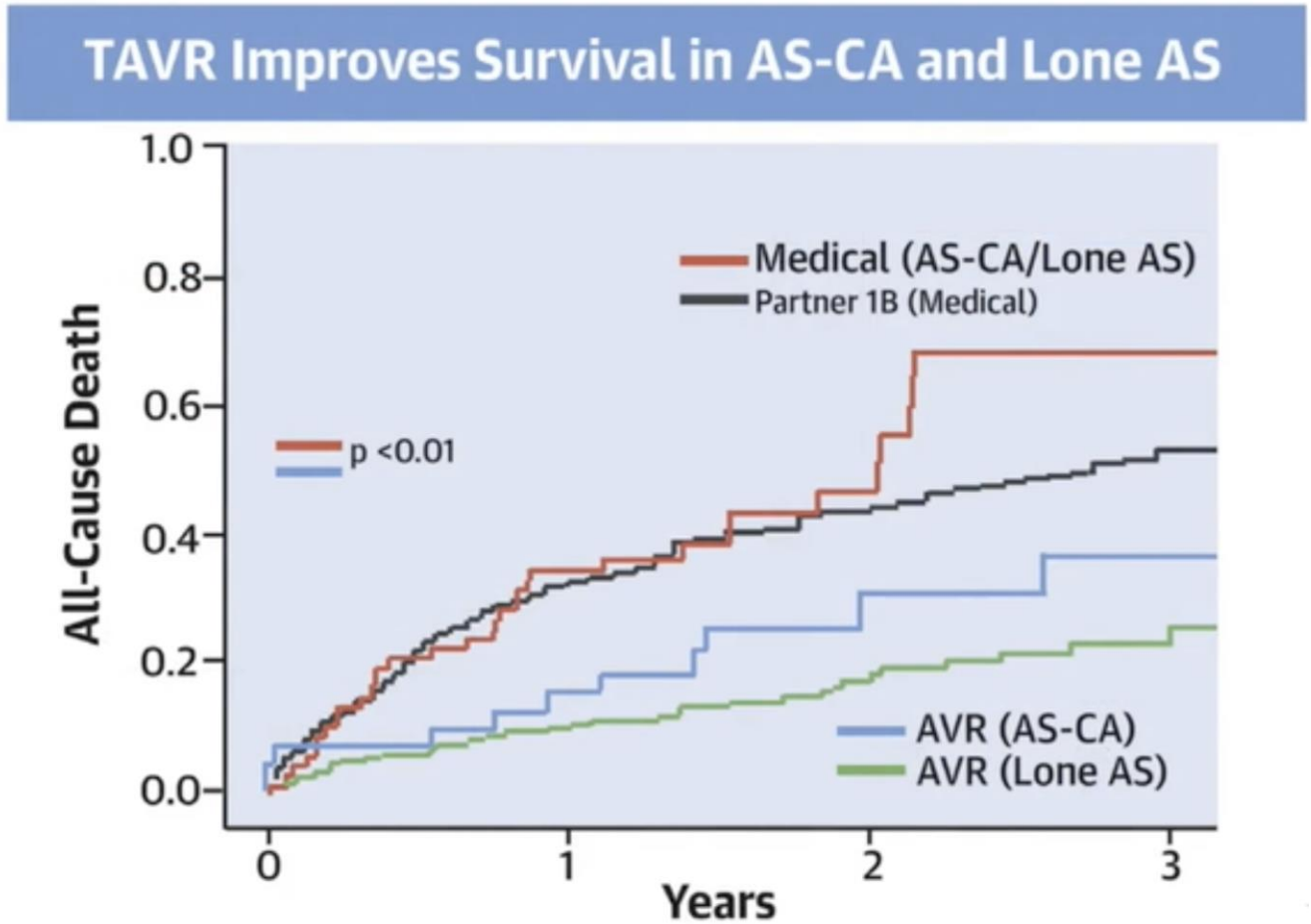

Nitsche C, …, Mascherbauer J, Treibel TA et al JACC 2020

Treatment of AS and concomitant TTR amyloidosis: TAVR

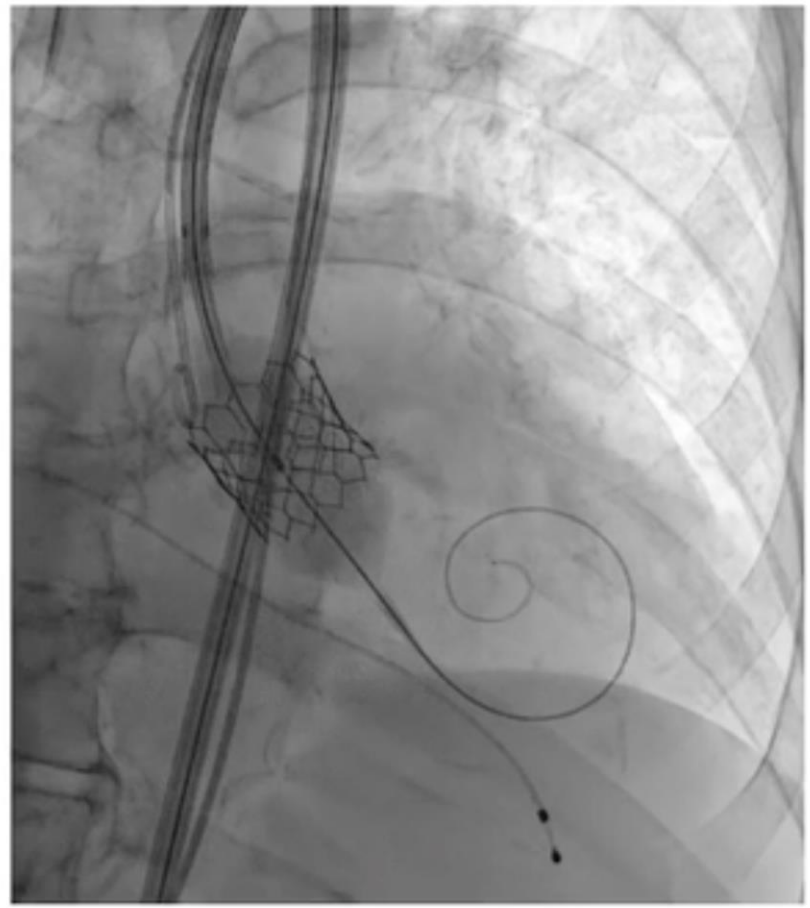

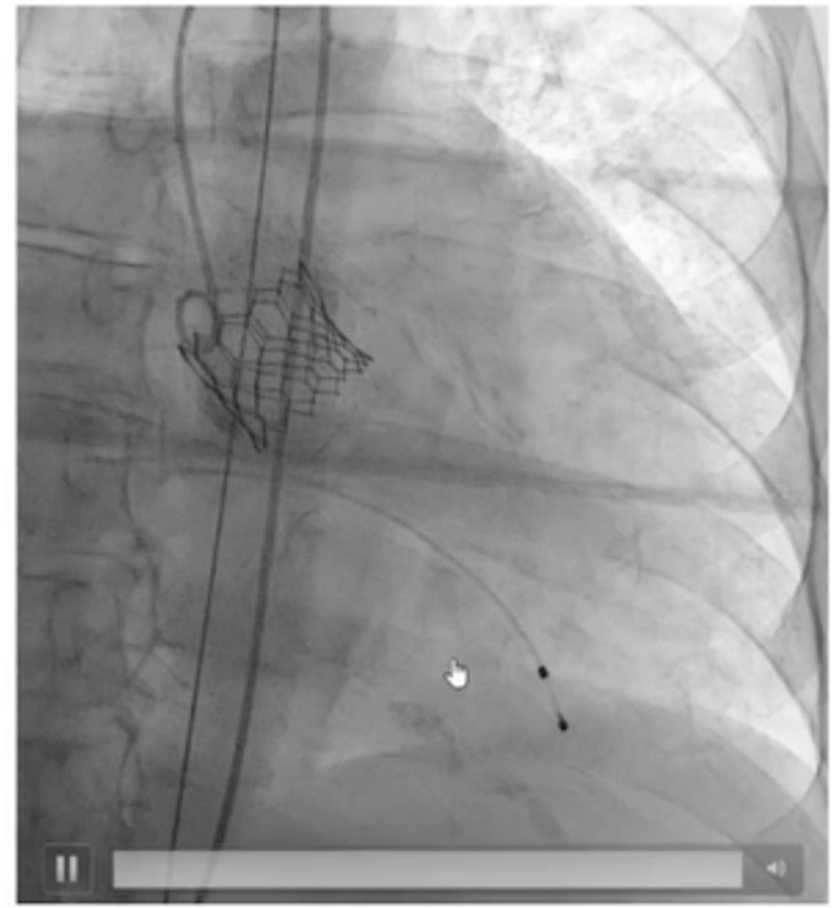

Follow-up

- Improvement in NYHA class from III/IV to II, 6MWT from 230m to 472m
- LVF remained reduced, AV mean△p 9mmHg, peak△p 12mmHg
- Start with Tafamidis

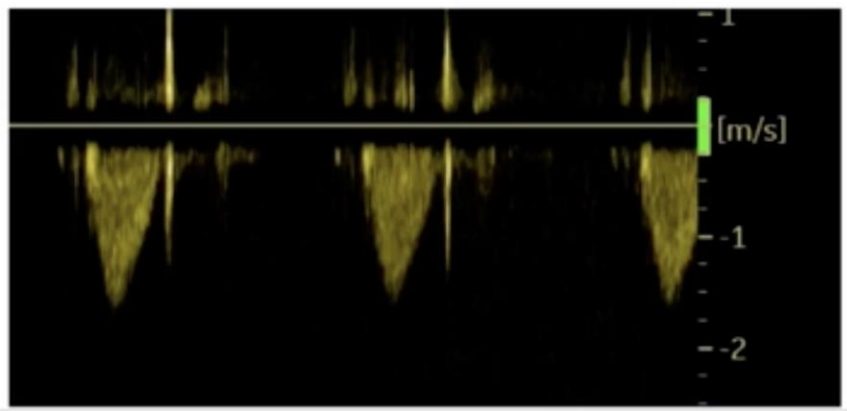

85 y/o male presented to the emergency department with acute dyspnea

- history of previous cardiac and pulmonary disease, CKD III, Diabetes type II, Disability
- Laboratory:
  - NT pro-BNP: 2320 ng/ml
  - Troponin T: 130 pg/ml

  - NT pro-BNP: 1820 ng/L
  - Creatinine: 1.5 mg/dl
  - **Troponin T: 90 pg/ml**

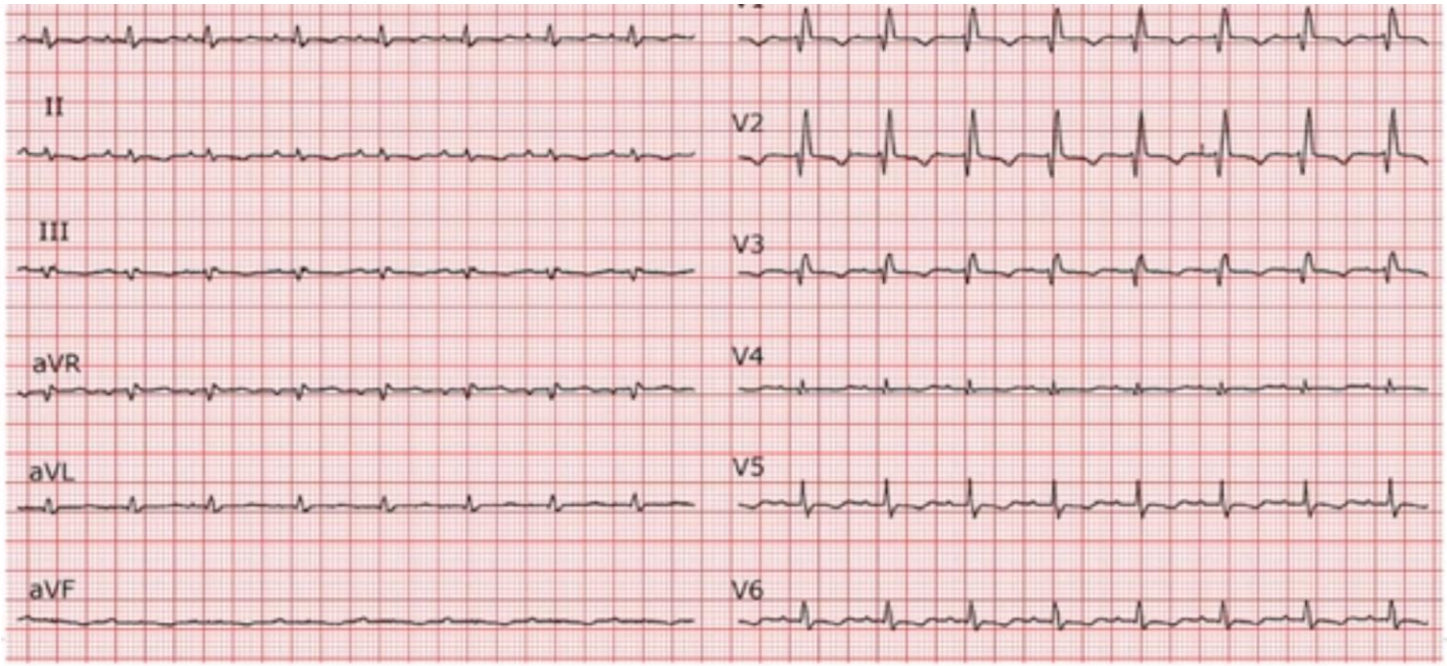

Diagnosis of Aortic Stenosis and CA-TTR

TAVR? YES

TAFAMIDIS?

Cost-Effectiveness of Tafamidis Therapy for Transthyretin Amyloid Cardiomyopathy

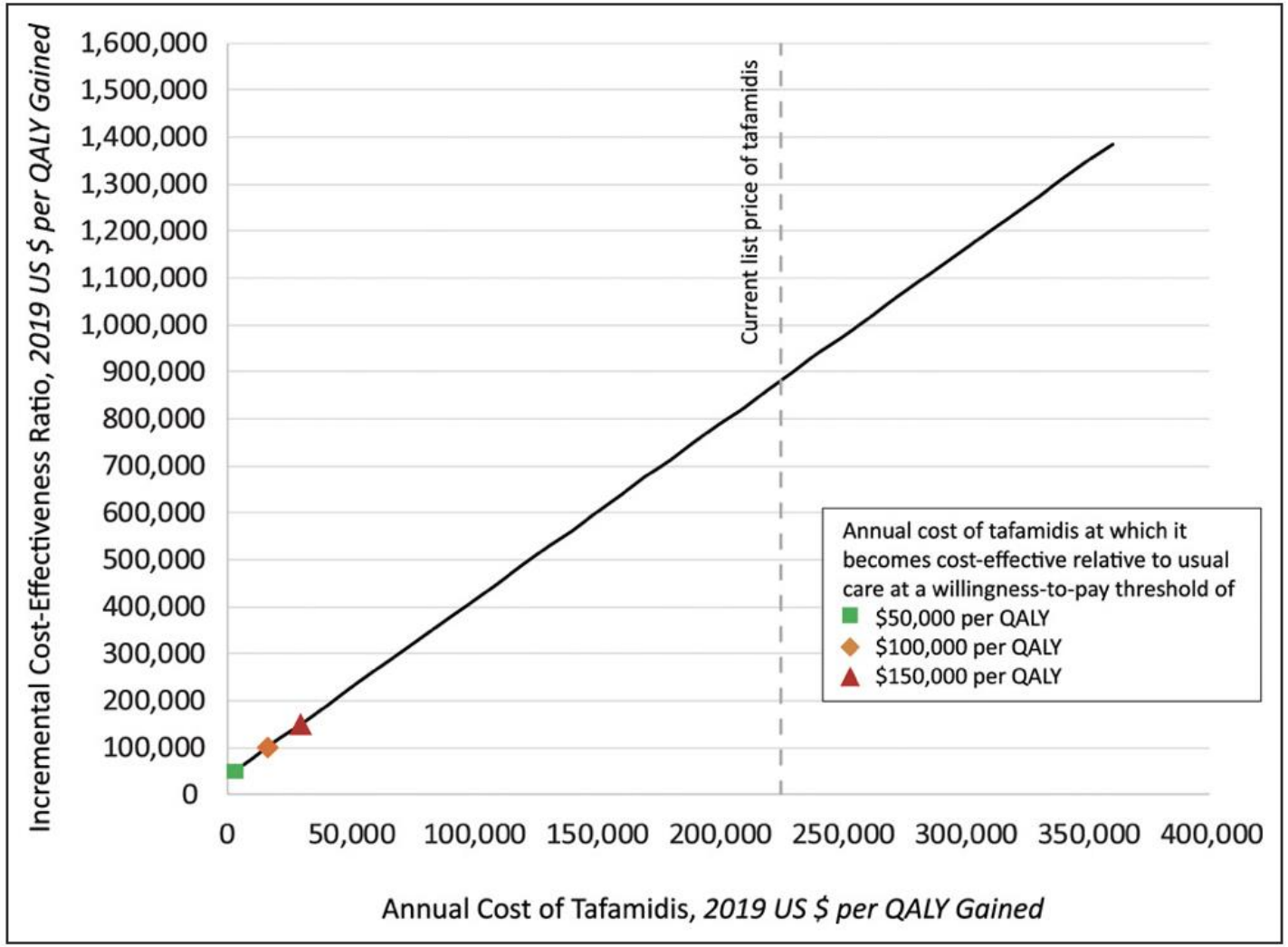

Circulation 2020; 141: 1214-1224

Cost-Effectiveness of Tafamidis Therapy for Transthyretin Amyloid Cardiomyopathy

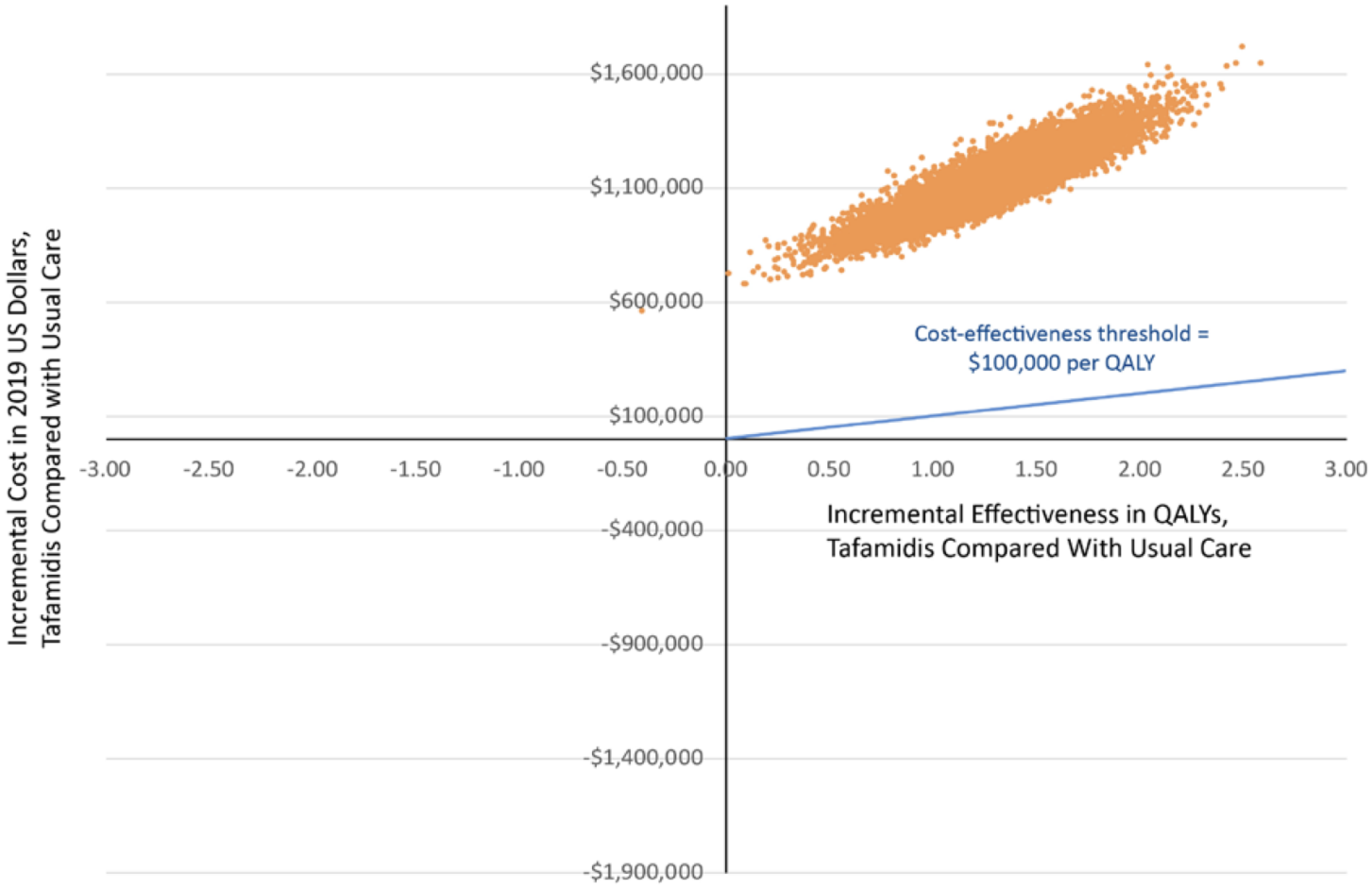

QALY – quality-adjusted life year.

Circulation 2020; 141: 1214-1224

Prevalence of dual AS and CA

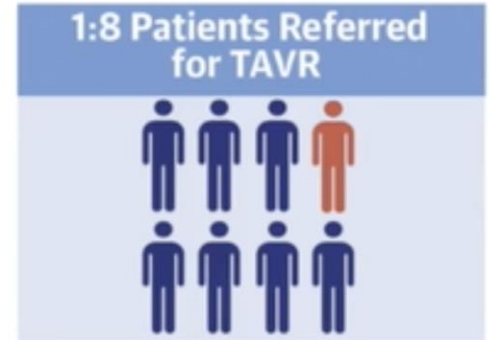

Author or Study Name, Year	Study Context	Diagnosis Modality	N	Prevalence of CA (%)	Male (%)	Mean Age (yrs)	Lower Age Limit (yrs)
Nietlispach et al., 2012	Autopsy after TAVR	Histology (Autopsy)	17	29	33	85	76
Longhi et al., 2016	referred for AVR (surgical or transcatheter)	Bone scintigraphy if echo suspicious ("red flags")	43	11.6	80	84	76
Treibel et al., 2016	referred for SAVR	Histology (surgical)	146	6% in age >65 yrs	66%	67	75
Castaño et al., 2017	referred for TAVR	Bone scintigraphy	151	16	92	86	≥65*
Cavalcante et al., 2018	moderate-severe AS referred to CMR	LGE pattern on CMR	113	16% in age >74 yrs	89	88	>60
Scully et al., 2020	considered for AVR (surgical or transcatheter)	Bone scintigraphy	200	13.9	50	85	≥75
Nitsche et al., 2020	referred for TAVR	Bone scintigraphy, CMR, EMB	191	8.4	49.7	81	NA
Rosenblum et al, 2020	Patients with AS after TAVR	Bone scintigraphy, CMR	204	13%	65	85	NA

AS and ATTR-wt are both age related diseases

- Aortic stenosis (AS) is present in up to 3% of patients ≥75 years old

Thaden JJ, Prog Cardiovasc Dis 2014

- Post-mortem studies indicate that at least 25% of individuals over age 80 have histologic evidence of amyloid deposits in the heart

Tanskanen M, Ann Med 2008

UNDERDIAGNOSIS

clinical features mimic other cardiac pathologies that frequently co-exist

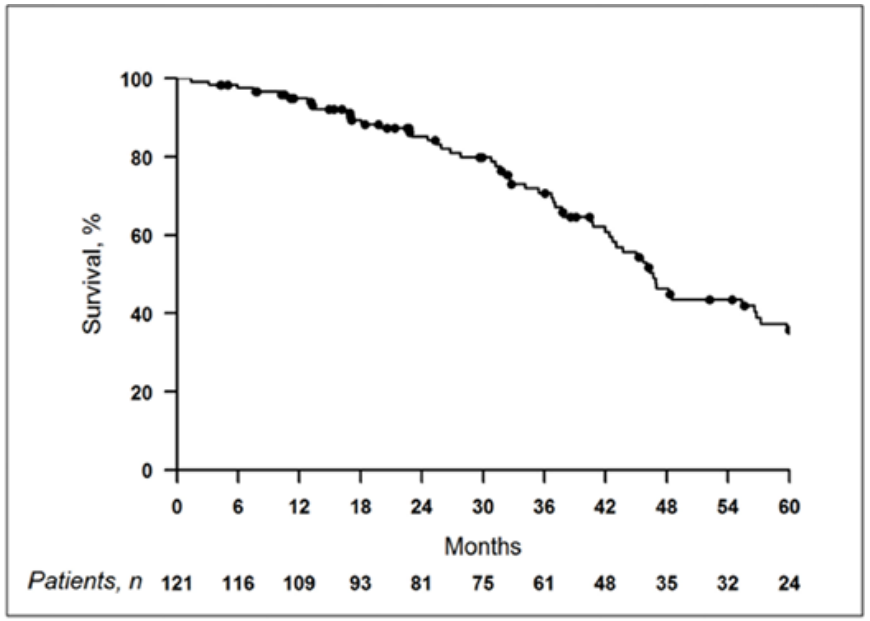

Connors, Circulation 2016

Diagnosis and treatment of cardiac amyloidosis: a position statement of the ESC Working Group on Myocardial and Pericardial Diseases

Left Ventricular Wall Thickness ≥ 12 mm

+ ≥1 of

- Heart failure in ≥ 65 years
- Aortic stenosis in ≥ 65 years
- Hypotension or normotensive if previously hypertensive
- Sensory involvement, autonomic dysfunction
- Peripheral polyneuropathy
- Proteinuria
- Skin bruising
- Bilateral carpal tunnel syndrome
- Ruptured biceps tendon
- Subendocardial/transmural LGE or increased ECV
- Reduced longitudinal strain with apical sparing
- Decreased QRS voltage to mass ratio
- Pseudo Q waves on ECG
- AV conduction disease
- Possible family history

Impact on outcome

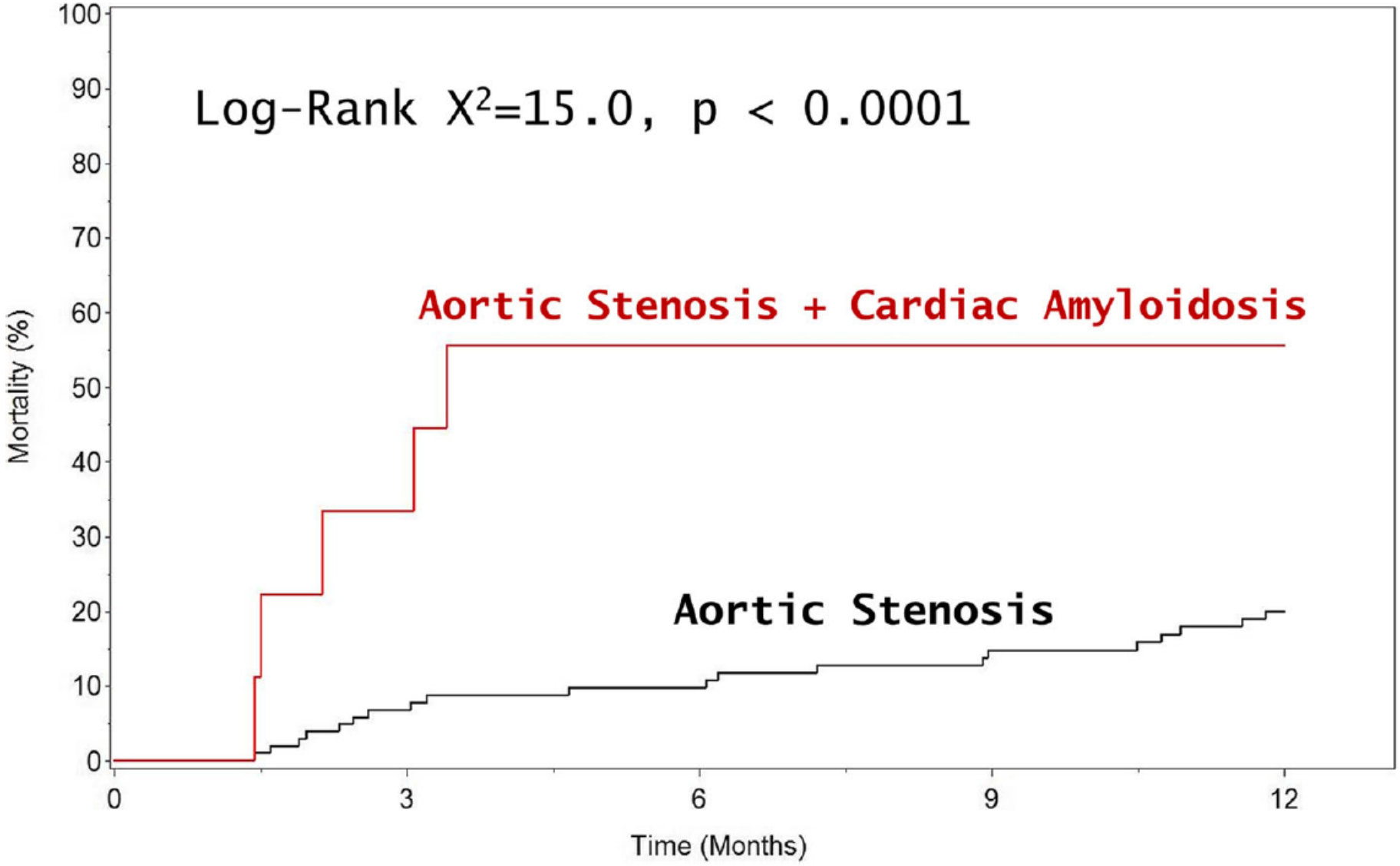

Cavalcante et al. Journal of Cardiovascular Magnetic Resonance (2017

AS and ATTR: Pathophysiology

100 surgically resected heart valve specimens (AS)→n=74 Amyloid

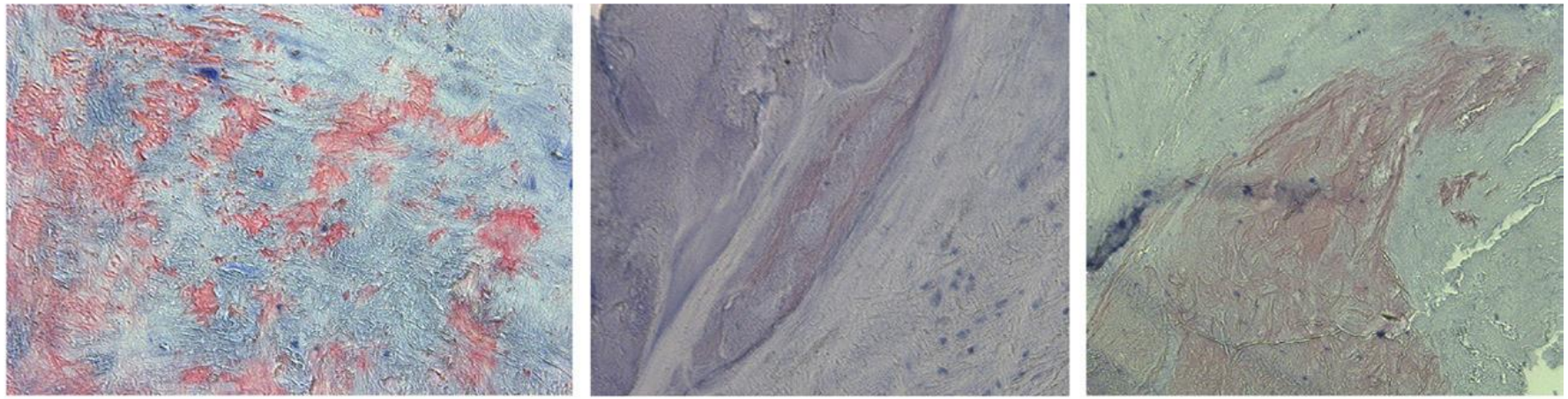

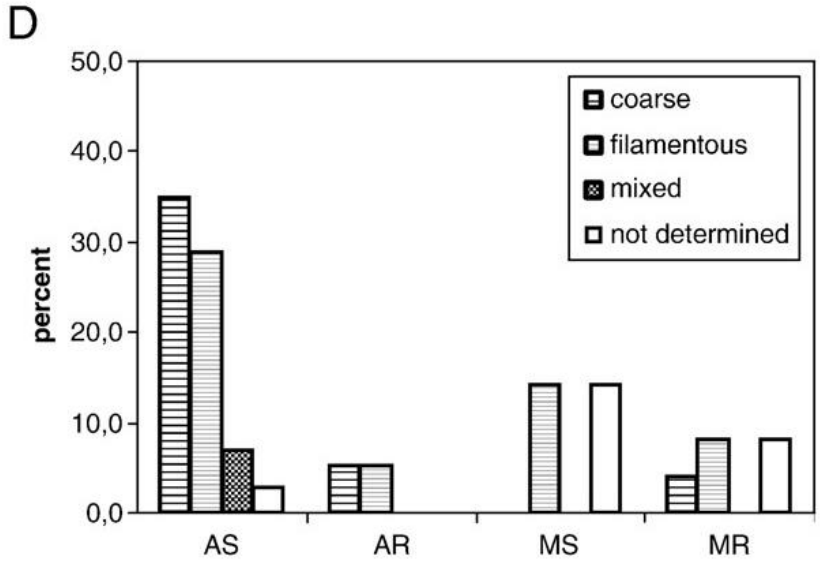

Kristen AV, Cardiovasc Pathol 2010

Histological analysis: amyloid deposition

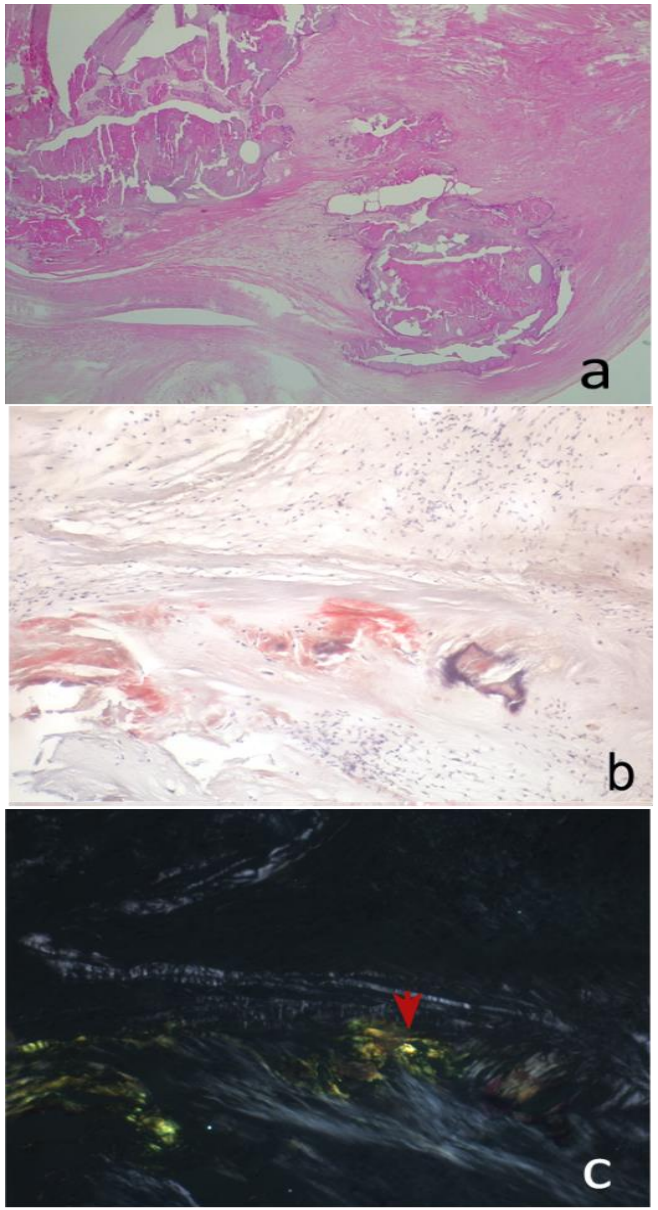

48 AS patients: explanted AVs → **17 POSITIVE VALVES (35%)**

43 controls: explanted AVs for AV insufficiency → **NONE POSITIVE VALVES**

Bone scintigraphy: No cardiac uptake in patients with valvular amyloid deposition

Serum Free Light Chain ratio: normal value in all patients

VALVULAR AMYLOID DEPOSITION CAN BE ISOLATED

Proteomic analysis

2 AVs positive for amyloid deposition at histology
4 AVs negative (used as controls)

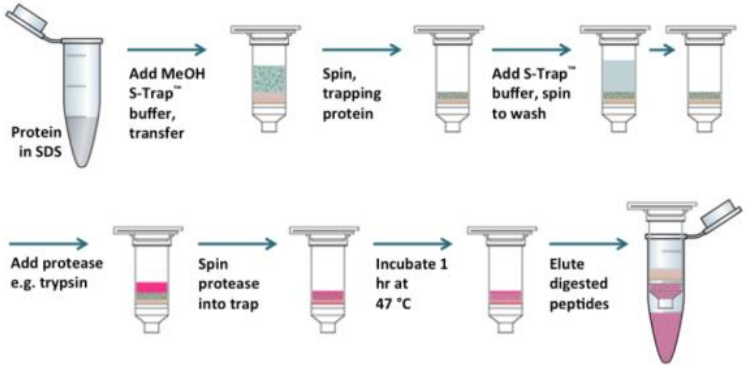

Which protein/s

Proteomic analysis on differentially expressed proteins

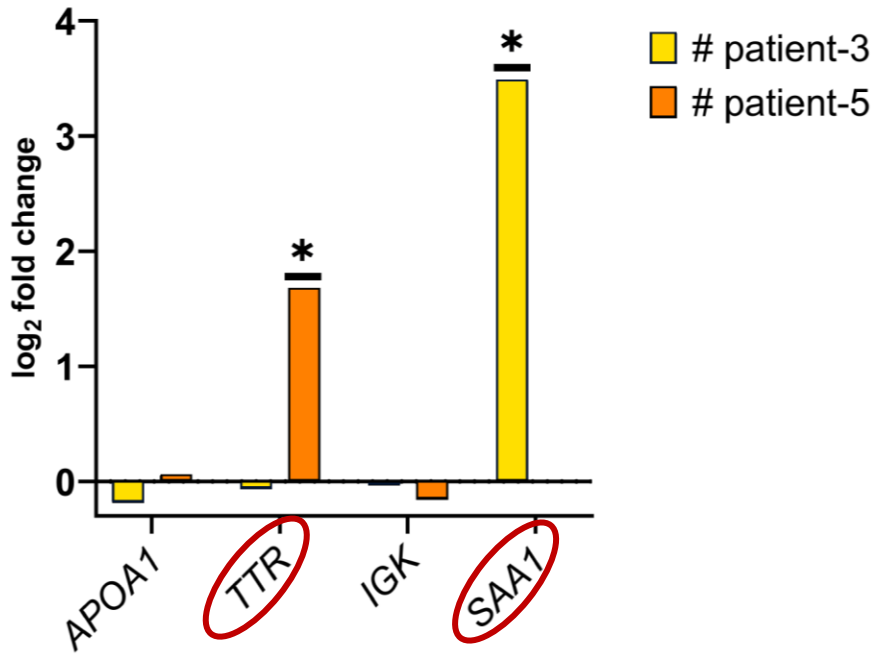

Representative set of proteins related to cardiac amyloid fiber formation; Statistically significant proteins are reported with an asterisk.

Immunohistochemistry

17 amyloid-positive valves →
Specific antibodies for SAA1 and TTR

positive in 75% of the samples:
→**SAA1**: 6 AVs (35%)
→**TTR**: 3AVs (18%)
→**SAA1+TTR:** 6 AVs (35%)

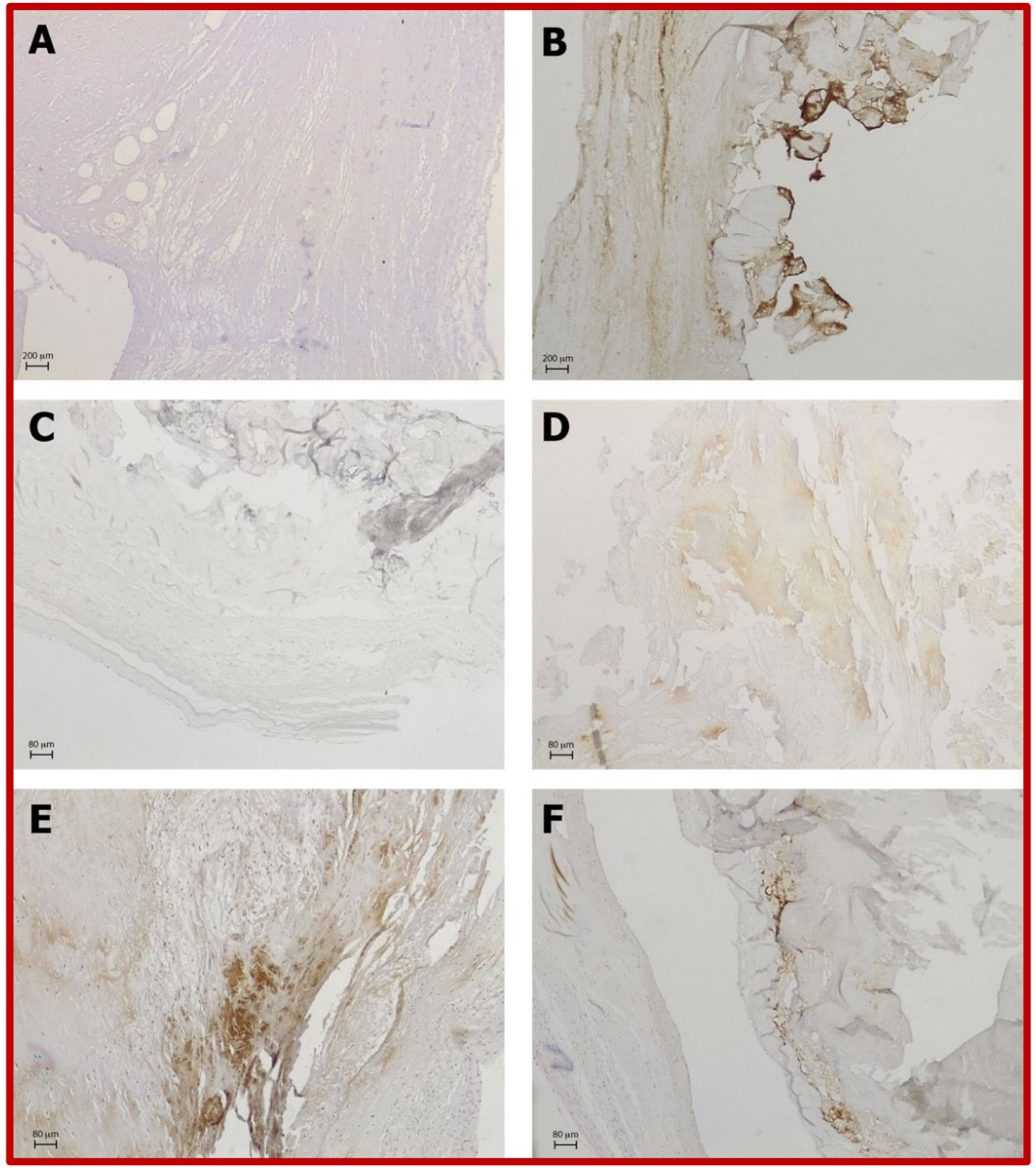

A) Negative and B) positive immunostaining for SAA1;

C) Negative and D) positive immunostaining for TTR;

E) Positive immunostaining in the same valve for SAA1 and F) TTR, respectively

SAA1 as amyloidogenic protein

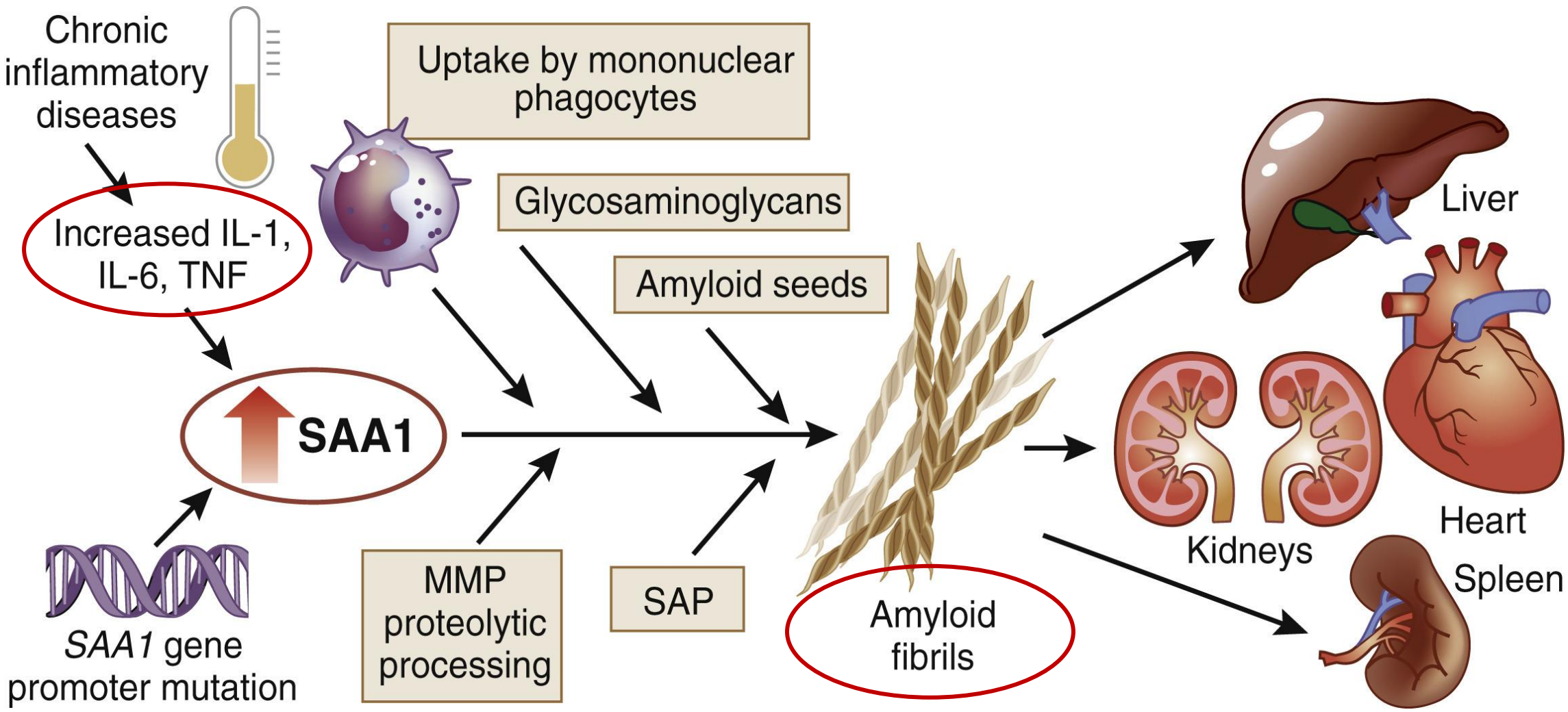

Obici L, Kidney Int. 2022

SAA1 gene expression in human valve interstitial cells (VICs)

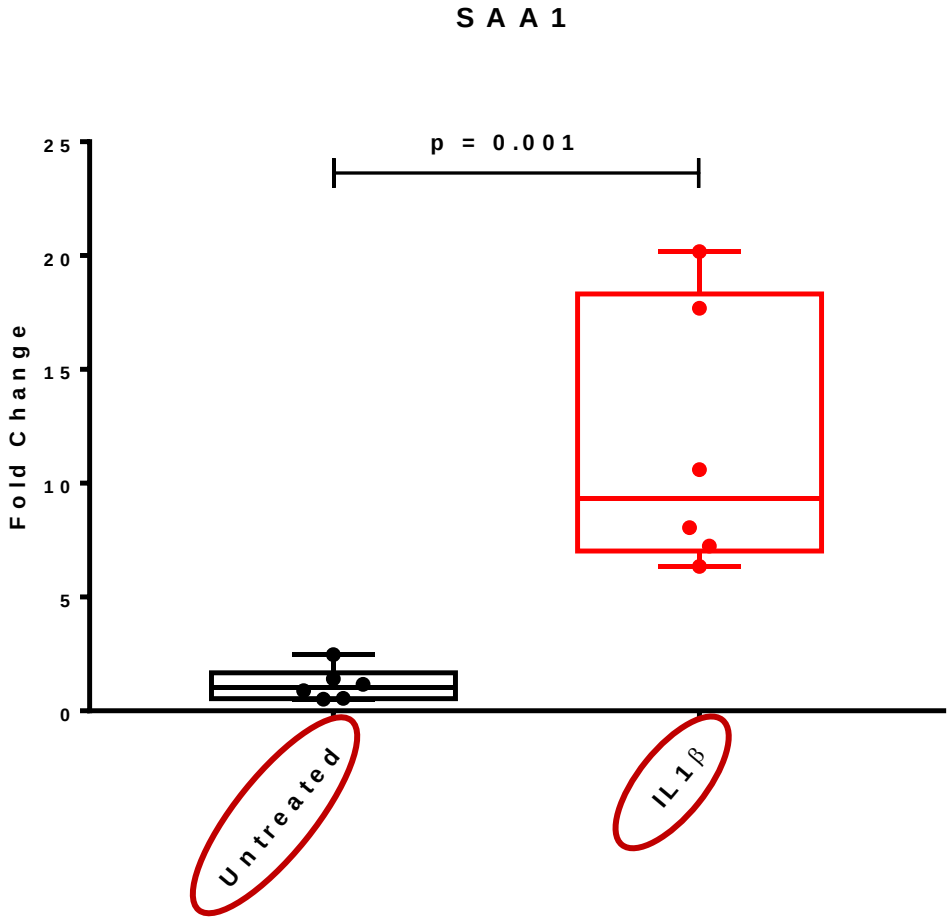

- Box-Whisker plots representing SAA1 gene expression in VICs isolated from human stenotic aortic valves (n = 6) in basal conditions (untreated) and after IL-1β stimulation. (+11,7 ± 2,4 fold)

local inflammation may sustain SAA1 levels over time and may promote protein misfolding within the AVs leaflets

Follow-up

- Improvement in NYHA class from III/IV to II, 6MWT from 230m to 472m
- LVF remained reduced, AV mean△p 9mmHg, peak△p 12mmHg
- Start with Tafamidis